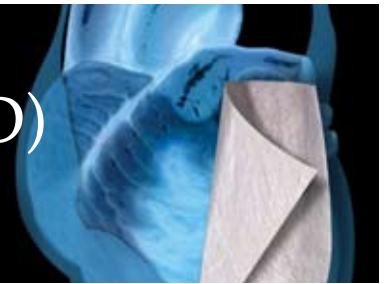


# Left Ventricular Assist Device (LVAD) CASE REPORT

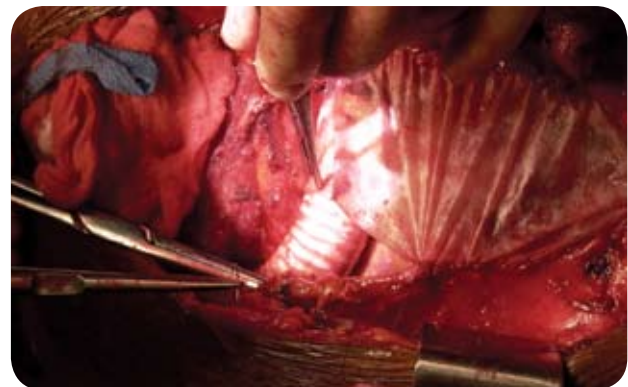


**INSTITUTION: The St. Vincent Heart Center of Indiana, Indianapolis, Indiana**

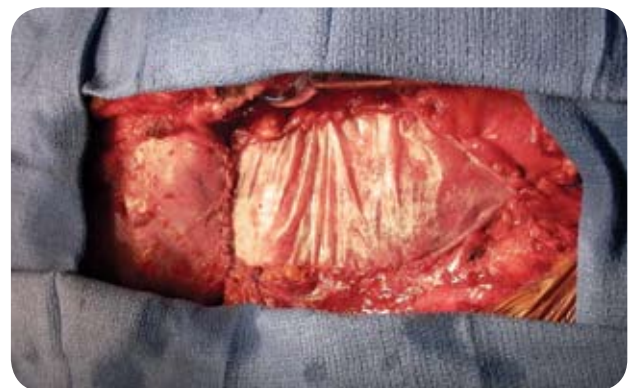**SURGEON: Christopher T. Salerno, MD**

A series of 21 Class IV heart failure patients were evaluated and treated using the CorMatrix® ECM™ for Pericardial Closure during left ventricular assist device (LVAD) implantation. In all cases the LVAD was offered as either a bridge to transplant, bridge to decision, or destination therapy. In each case the ventricular assist device was placed via a median sternotomy and efforts were made to preserve the native pericardium. In cases where a redo-sternotomy was required, the native pericardium was fully mobilized prior to LVAD implantation. All devices were placed using left ventricular apical cannulation (for the LVAD inflow) and the ascending aorta for the anastomosis of the LVAD outflow conduit. Following the LVAD implantation and after obtaining adequate hemostasis to allow closure, the CorMatrix ECM was used to replace or augment the native pericardium. After two chest tubes were placed inside the pericardium, the CorMatrix ECM was sewn to the native pericardium using a running 4-0 Prolene suture. Care was taken to ensure that the CorMatrix ECM was in direct contact with native tissue on all four sides. When possible the LVAD outflow graft was placed completely inside the pericardial space; when this was not possible the outflow graft was wrapped in a separate sheet of CorMatrix ECM. Prior to sternal closure another drain was placed anterior to the reconstructed pericardium. To date, several patients have gone back to surgery for transplant and in all cases sternal re-entry was easily performed without incident. On redo cases we routinely perform a sub-sternal dissection prior to dividing the sternum. In all cases no more than minimal retro-sternal adhesions were encountered. This facilitated a rapid and safe

redo-sternotomy. In our experience the intra-pericardial adhesions varied significantly from patient to patient. In one case the CorMatrix ECM was histologically identified as native pericardium. There have been no CorMatrix ECM related complications. Overall we have experienced clinical improvement through the use of the CorMatrix ECM, which has decreased the time and complexity of redo operations.



The inferior and diaphragmatic pericardium being restored with the CorMatrix ECM over the outflow graft of the LVAD.



The LVAD is completely covered by the ECM utilizing the required circumferential closure technique with a running 4-0 Prolene.